

Diagnosis of TB in Children

Dr Jacquie Narotso Oliwa

Objectives

- To identify the common clinical presentations of TB in children
- Overview of diagnostic measures
- To understand a simplified approach to the diagnosis of TB in children

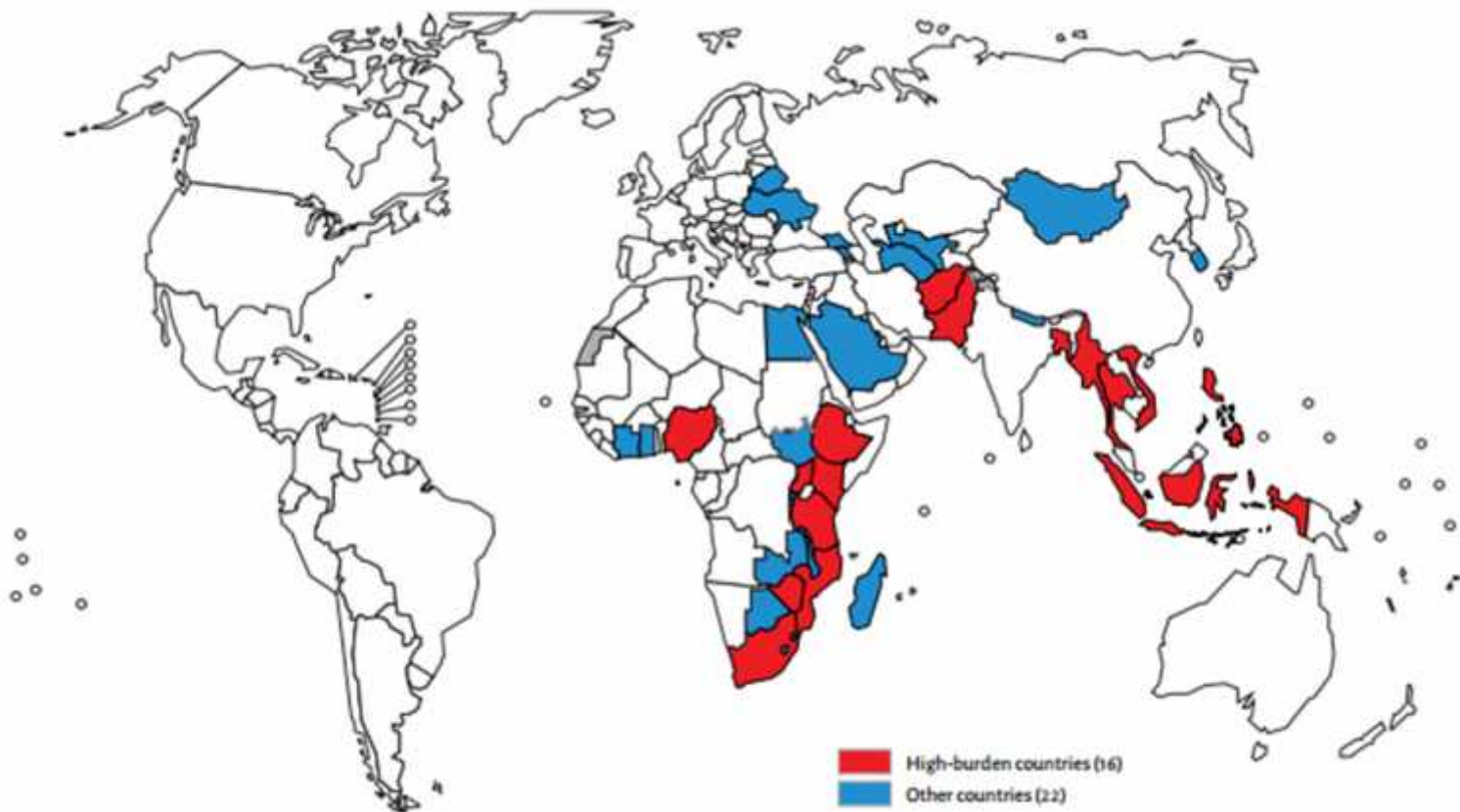
Introduction

- Tuberculosis (TB) is a major global health problem: leading cause of death from infectious diseases worldwide.
- In 2014, there were an estimated 9.6 million new TB cases: **1.0 million among children**.¹
- There were also 1.5 million TB deaths of which \approx **140 000 were children**.¹
- One third of the world is infected with *M.tb* but \approx 90% can resist overt disease; except children whose risk ranges from 20-40%²

¹World Health Organisation. Global Tuberculosis Report 2015

²Perez-Velez CM, Marais BJ. 2012. Tuberculosis in children. N. Engl. J. Med. 367:348 –361

TB High Burden Countries¹



¹World Health Organisation. Global Tuberculosis Report 2015

Diagnosing pulmonary TB in children

Recommended approach to diagnose PTB in children

1. Careful history

- Includes history of TB contact
- Symptoms suggestive of TB


2. Clinical examination

3. Tuberculin skin test

4. Chest radiograph

5. Bacteriological confirmation (sputum for Xpert, culture and DST)

History of contact



- Note the following:-
 - ✓ Closeness of contact
 - ✓ Sputum smear result of index case (if known)
 - ✓ Timing of contact- children usually develop TB within 2 years after exposure and most (90%) within the first year
- Always ask about anyone in household/in contact with child at school with unexplained cough

Symptoms suggestive of PTB

- a. Cough for more than 2 weeks
- b. Fever for more than 2 weeks
- c. Lethargy / reduced playfulness / less active for more than 2 weeks
- d. Weight loss, no weight gain or poor weight gain (failure to thrive)

**PRESENCE OF TWO OR MORE OF THESE SYMPTOMS IS
SUGGESTIVE OF TB SO INVESTIGATE THE CHILD**

Physical signs suggestive of PTB

- Examine for any abnormal respiratory signs :
 - Increased respiratory rate
 - Signs of respiratory distress
 - In pleural effusion have a stony dull percussion note. Percussion may be normal
 - Abnormal breath sounds (e.g. wheezing, crackles, bronchial breathing).

Atypical presentation of PTB

In some cases, there may be atypical clinical presentations of PTB:

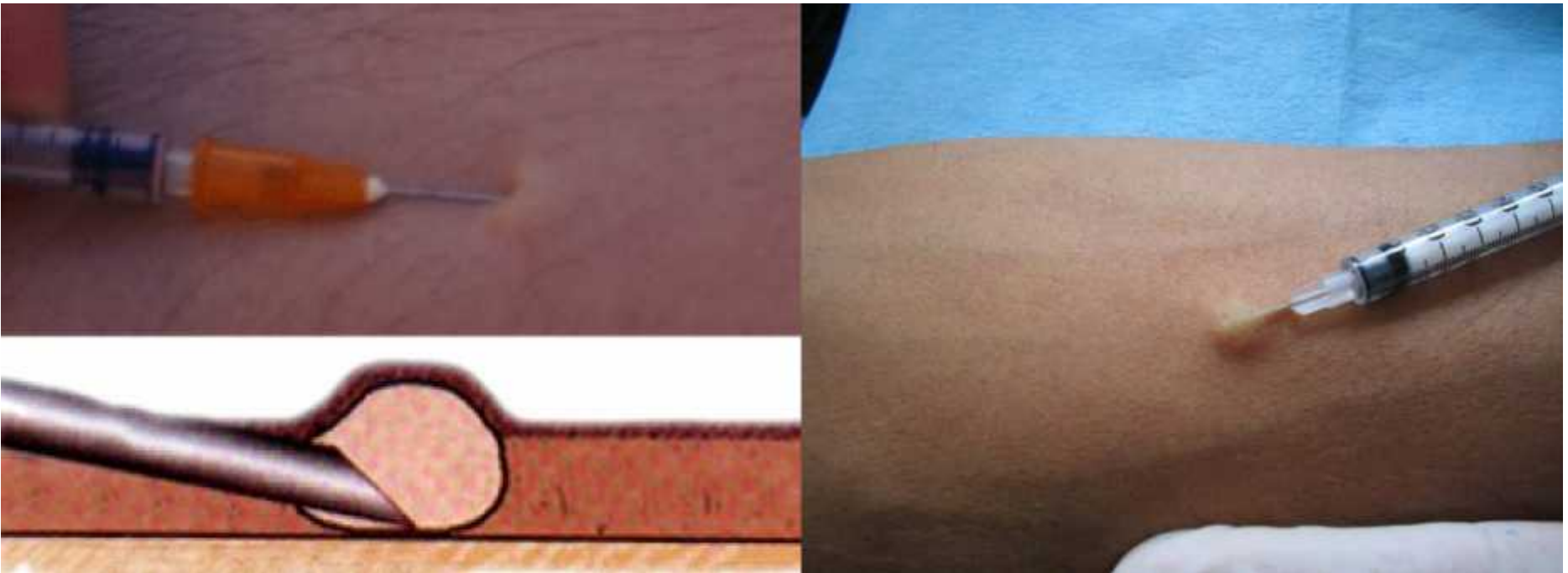
a. Acute severe pneumonia

- Fast breathing and chest in-drawing
- Especially in infants and HIV-infected children

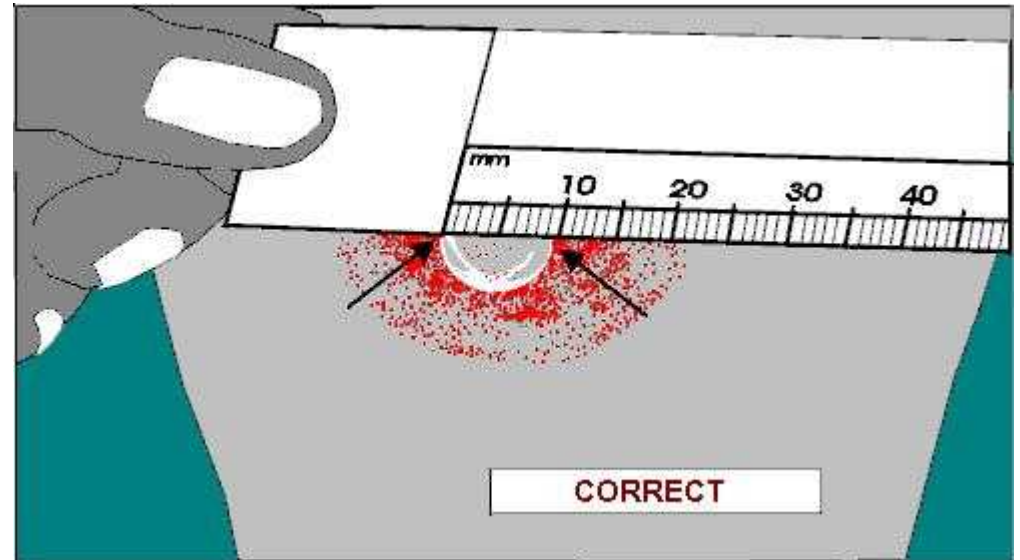
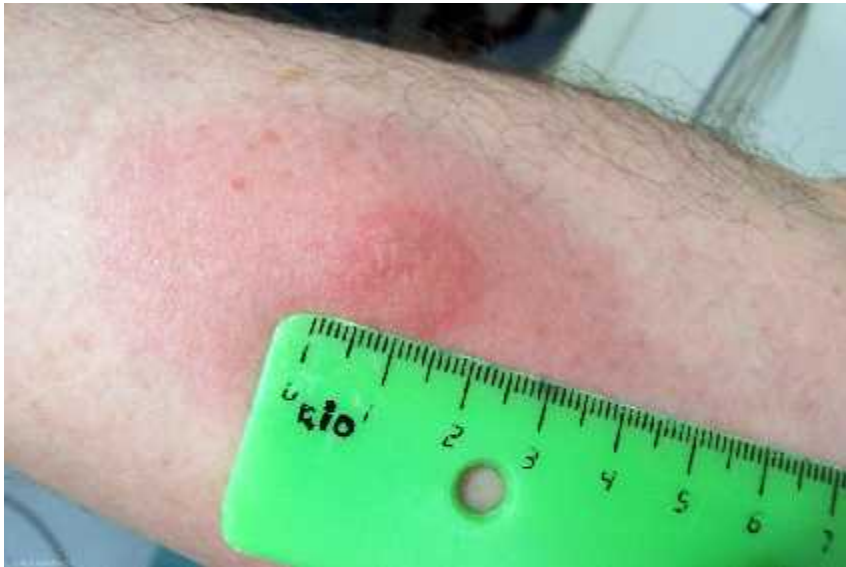b. Wheeze

- Suspect PTB when wheeze is asymmetrical, persistent and non responsive to bronchodilator therapy.

Mantoux test



TST interpretation



False Positive Mantoux:

- Infection with non tuberculous mycobacteria
- Previous BCG vaccination
- Incorrect method of TST administration
- Incorrect interpretation of reaction
- Incorrect bottle of antigen used

False Negative Mantoux:

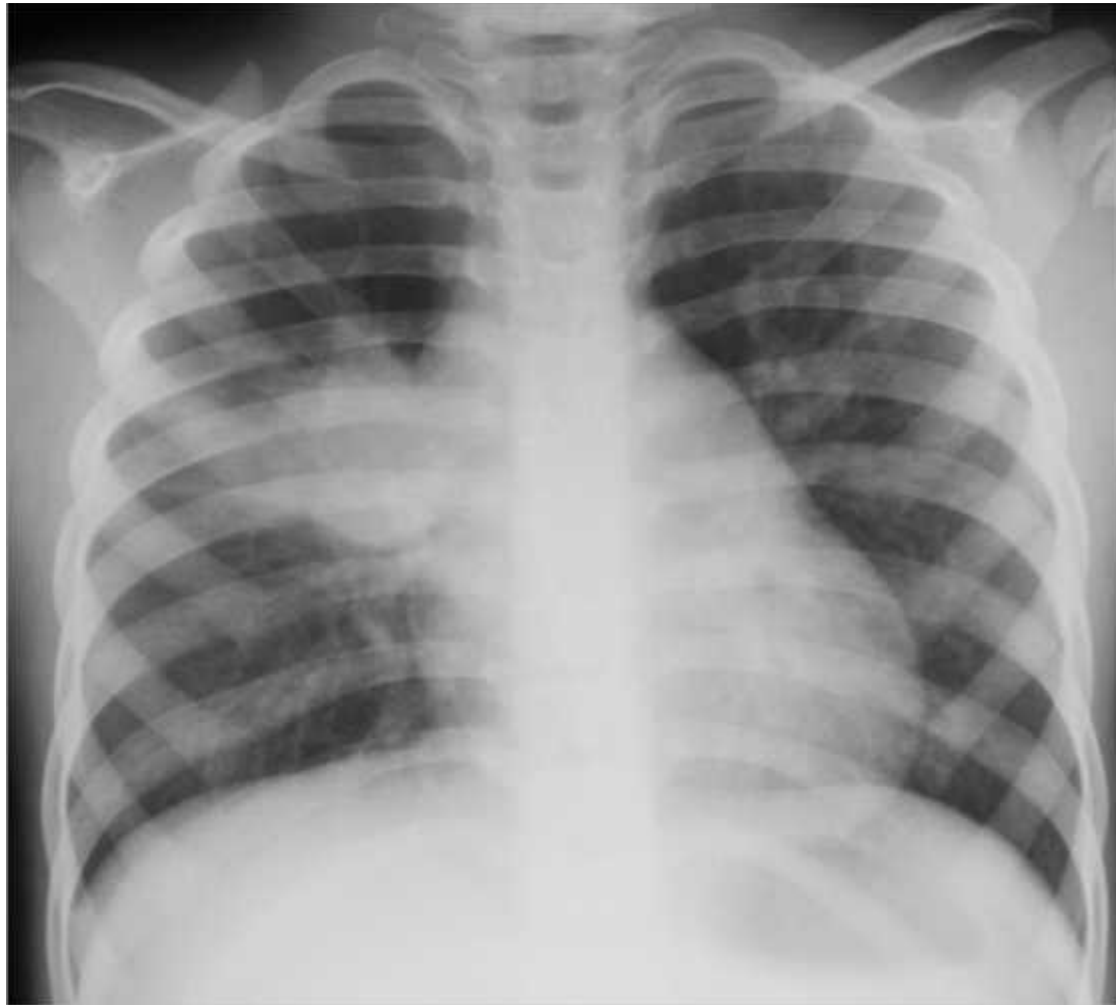- Cutaneous anergy
- Recent TB infection (within 8-10 weeks)
- Very young age
- Recent live-vaccine
- Overwhelming TB disease
- Some viral illnesses
- Incorrect administration
- Incorrect interpretation

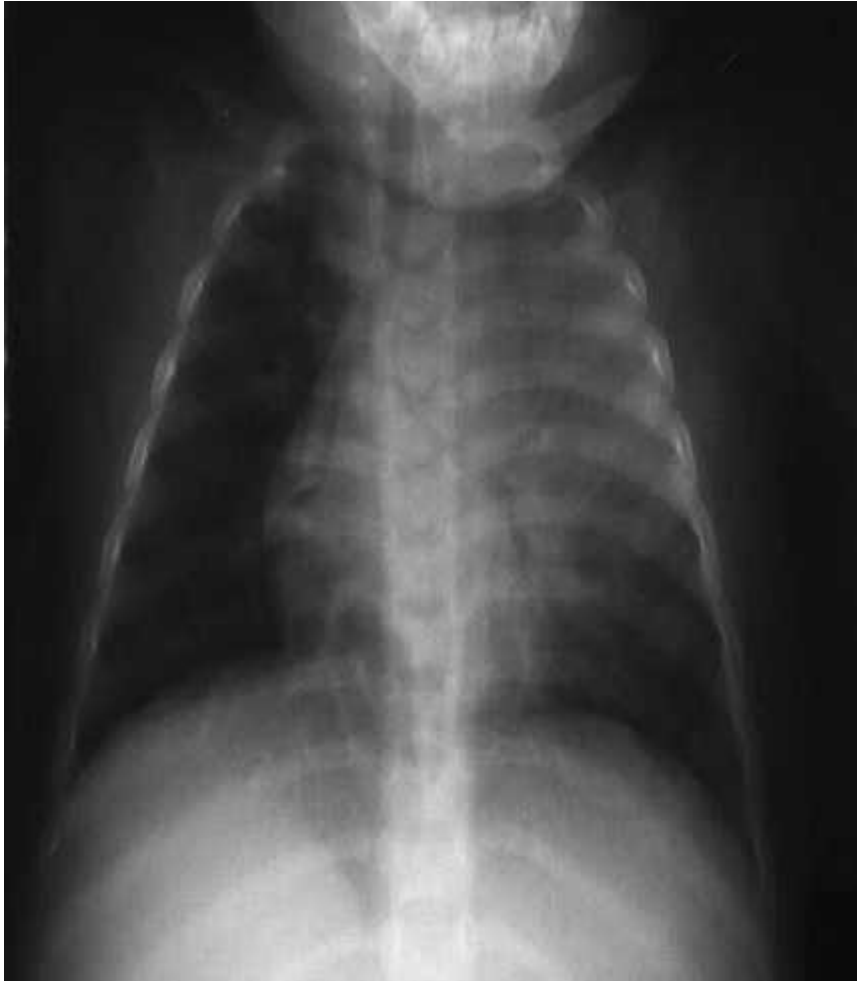Chest radiography

- Show enlargement of hilar, mediastinal, or sub-carinal lymph nodes and lung parenchymal changes.
- The most common findings are segmental hyperinflation then atelectasis, alveolar consolidation, interstitial densities, pleural effusion, and rarely, a focal mass.
- Cavitations are rare in young children.
- Sensitivity = 67% Specificity = 59%

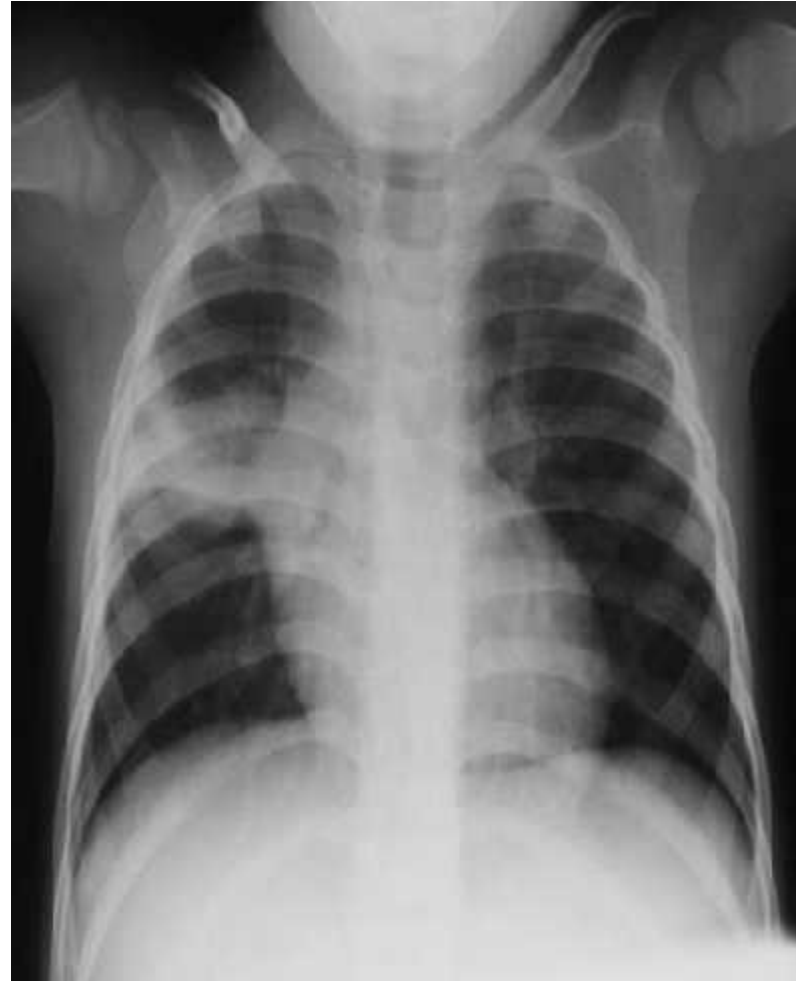Diagnostic accuracy of chest radiography in detecting mediastinal lymphadenopathy in suspected PTB. G H Swingler et al. *Arch Dis Child* 2005 90:1153-1156

Chest X-Ray pictures suggestive of pulmonary TB

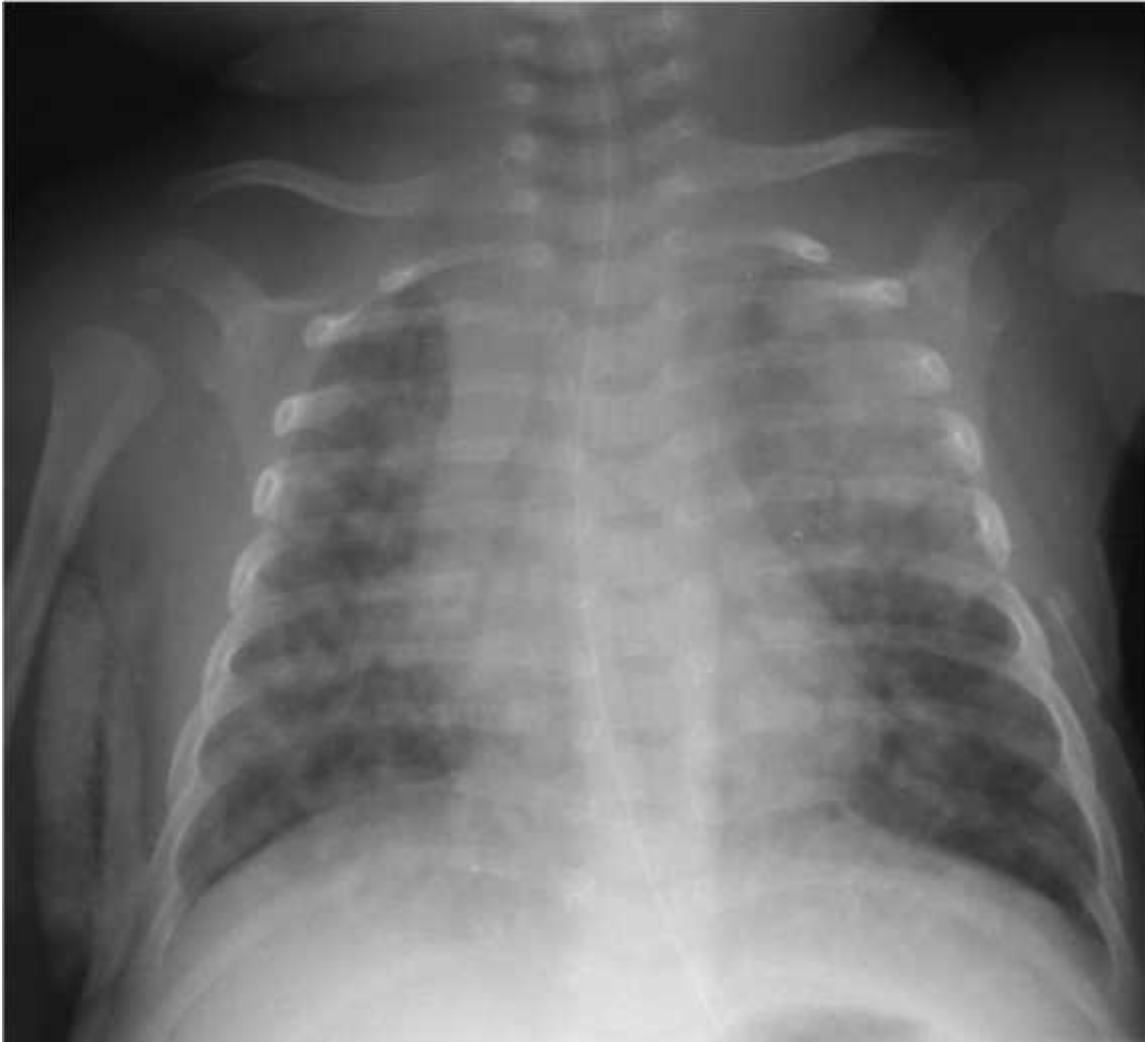



Left upper lobe opacification with narrowing and shift of left main bronchus



Right perihilar lymph node enlargement with opacity in the right mid zone



Infants can present as severe pneumonia with extensive parenchymal disease and respiratory distress that is challenging to differentiate from the many other possible cause of pneumonia in infants.

Laboratory investigations

- Collect the appropriate specimen for diagnosis
- In suspected PTB, use Sputum or gastric aspirate for microbiological examinations
- These specimens should be subjected to the appropriate test as below:
 - Microscopy for AFB (all specimens)
 - Xpert MTB/RIF (currently used only with sputum)
 - TB culture (all specimens from children under 5 years)
 - Histopathology (FNAs/biopsies)

Expectoration

- Older co-operative child, explain procedure
- Rinse mouth to remove food particles
- Take two deep breaths, holding after each inhalation, exhaling slowing. On third breath, forcefully blow air out then cough
- Hold sputum container close to lips and spit into it after a productive cough

Gastric Aspiration

- Highest yield if collected first thing in the AM
- Fast for 3-4hr, r/o bleeding diasthesis
- Position, measure NGT correctly, attach syringe to NGT, then insert
- Aspirate 2-5ml of gastric contents (test with litmus)
- If no fluid aspirate, insert 5-10ml NS and aspirate
- Transfer aspirate to container, add equal volume of sodium bicarbonate

Sputum Induction

- Give bronchodilator (salbutamol)
- Give nebulized hypertonic saline (3%) for 15 min
- Can give chest physio to mobilise secretions
- Older child can expectorate
- Younger: nasopharyngeal OR oropharyngeal suction
- C/I: not fasted; severe respiratory distress; altered consciousness; low plt; signif asthma; intubated

Xpert MTB/RIF®

- WHO endorsed, MOH approved. 129 machines in Kenya.
- Based on NAAT; results in 2h plus RIF resistance
- Compared with culture, the pooled sensitivities and specificities detection were 62% and 98%, respectively (15 studies, 3640 children)
- Xpert Ultra and Omni



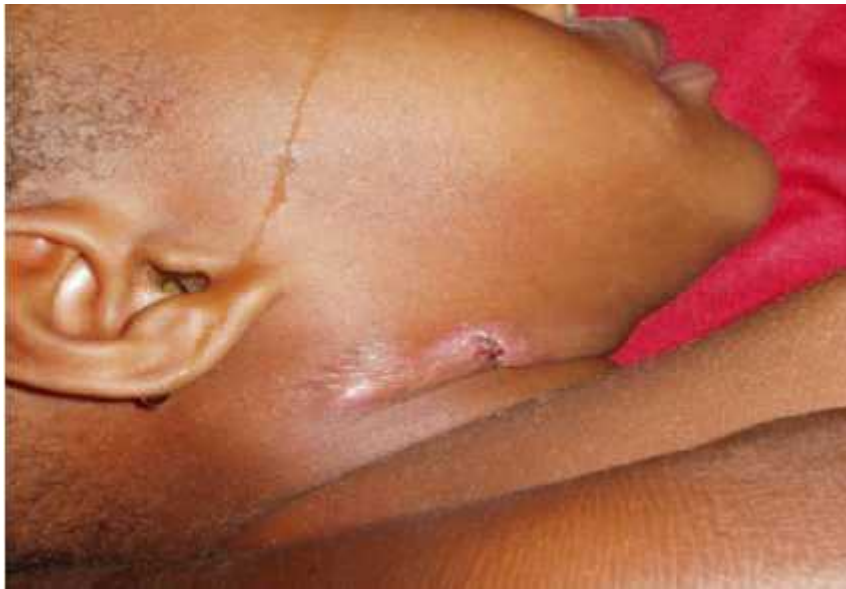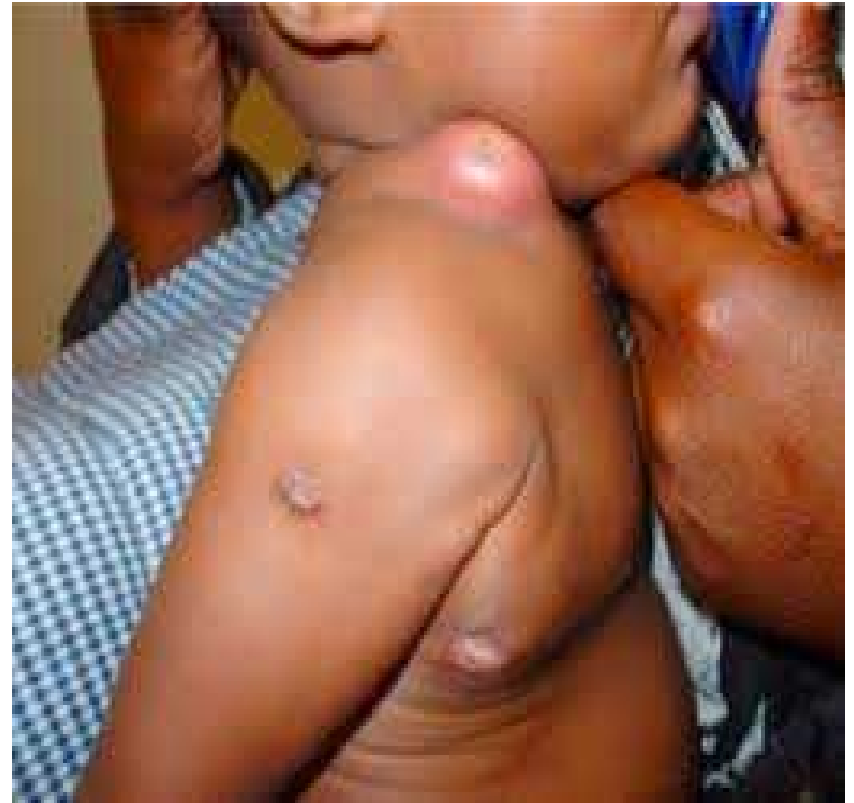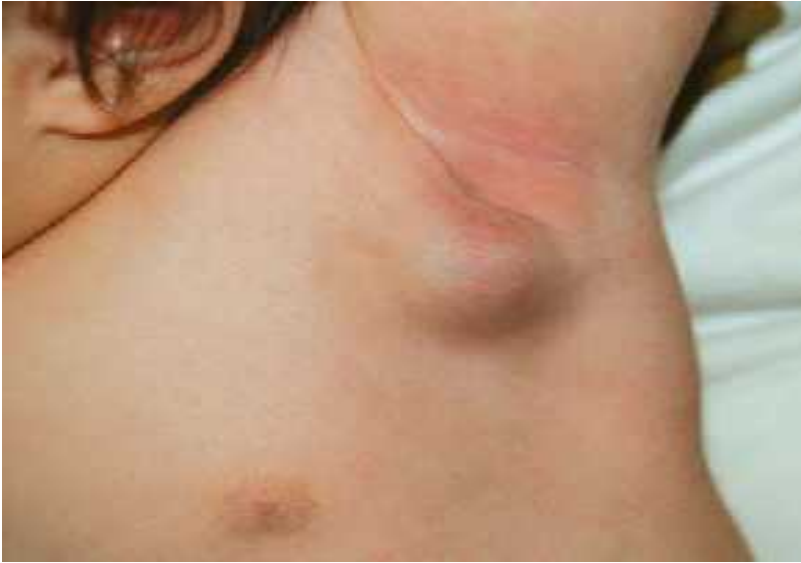Detjen AK, DiNardo AR, Leyden J, et al. Xpert MTB/RIF assay for the diagnosis of pulmonary tuberculosis in children: a systematic review and meta-analysis. *The Lancet Respiratory Medicine*; 3(6): 451-61.

Diagnosis of extra pulmonary TB in children

Types of childhood EPTB disease

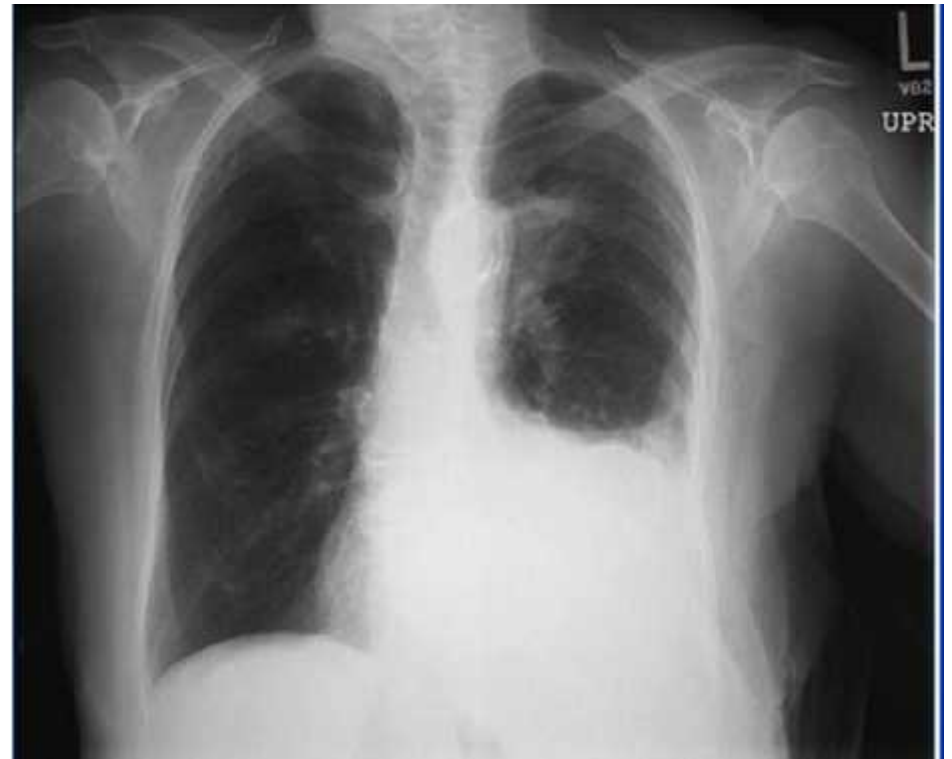	Malawi NTP, 1998
EPTB cases	808
Lymphadenitis	331 (41%)
Pleural effusion	101 (12%)
Spinal	83 (10%)
Pericarditis	60 (7%)
Abdominal	39 (5%)
Miliary	34 (4%)
Meningitis	30 (4%)
Bone disease	12 (1%)
Not indicated/others	118 (14.6%)

Tuberculous Adenitis



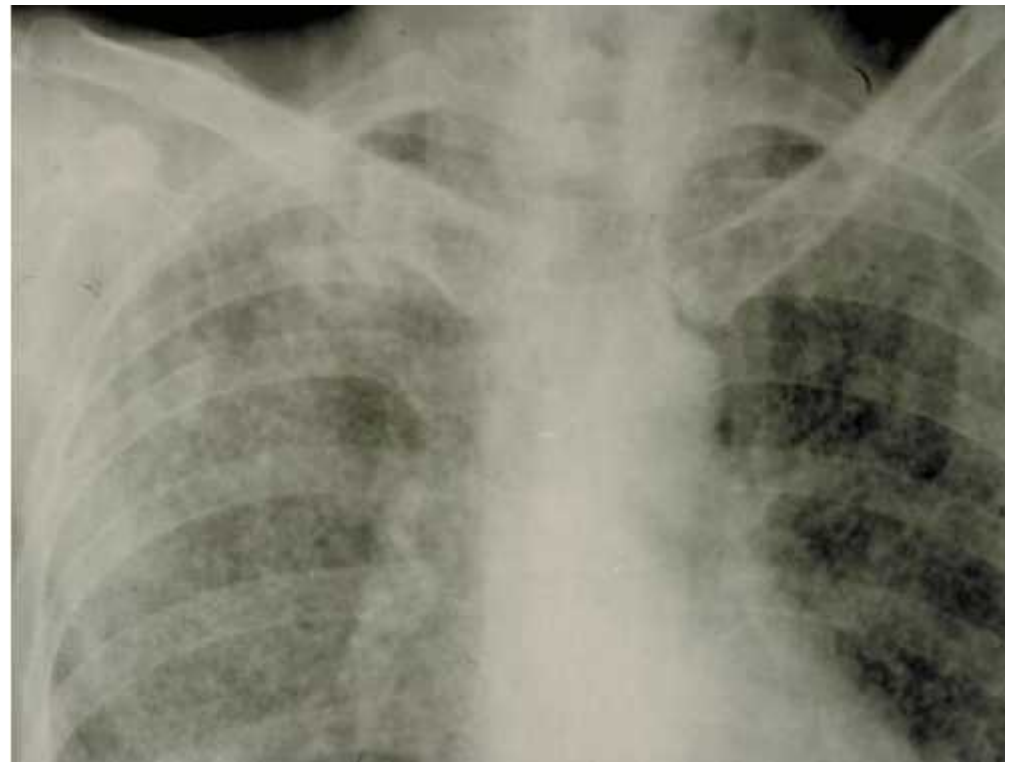
Tuberculous Pleural Effusion

- Pleuritic chest pain; dypnoea
- Pleural fluid analysis: High protein, high LDH, increased cell count (lymphocytes)
- Pleural biopsy: for histology and culture



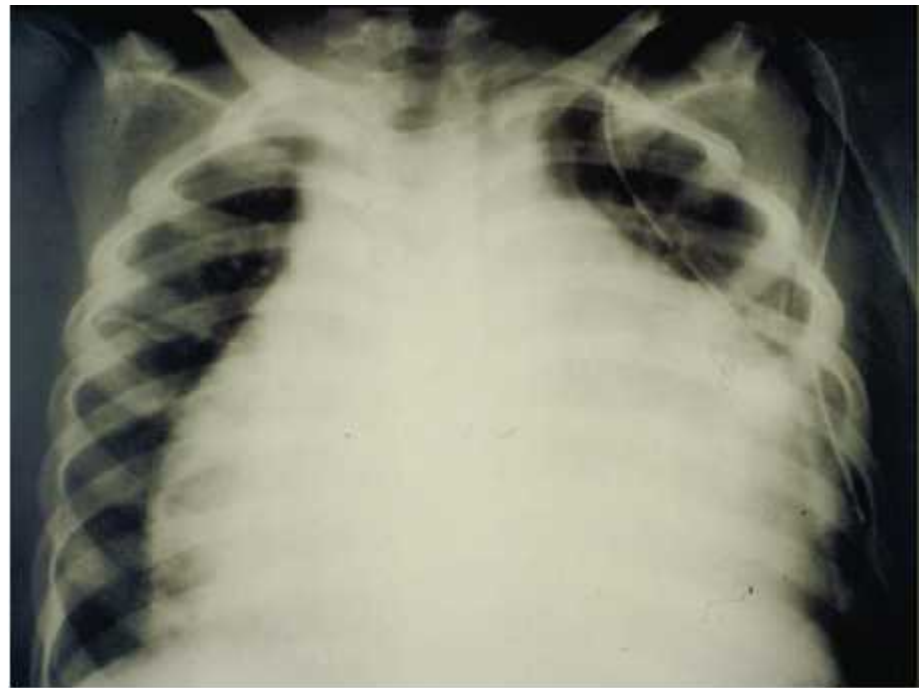
Miliary Tuberculosis

- Haematogenous spread of TB
- Presents as pyrexia of uncertain cause
- Enlarged liver and spleen are common
- Choroid tubercles on fundoscopy

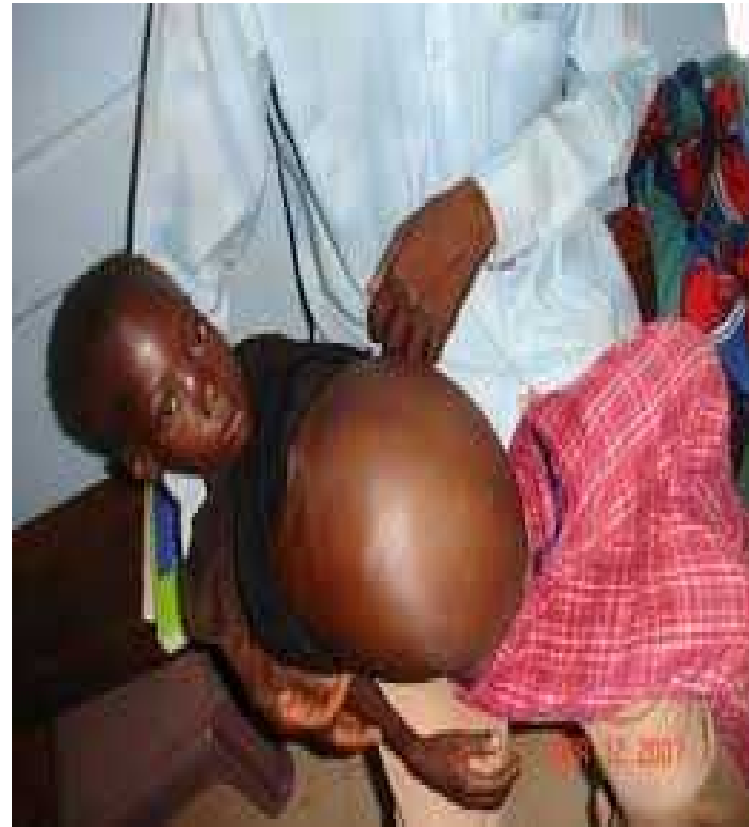
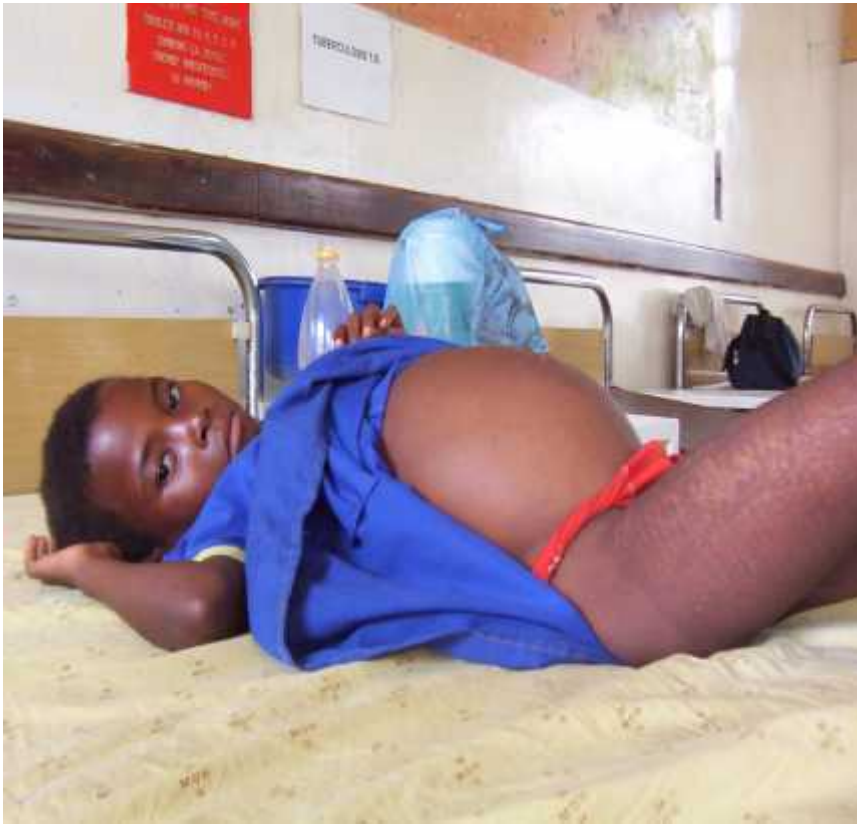
Tuberculous Pericarditis

- Tachycardia, tachypnea, leg edema, congested neck veins, distant heart sounds, pericardial rub
- Chest x-ray shows a large globular heart
- Echocardiography often required to confirm diagnosis



Tuberculous Peritonitis and Ascites



Investigations

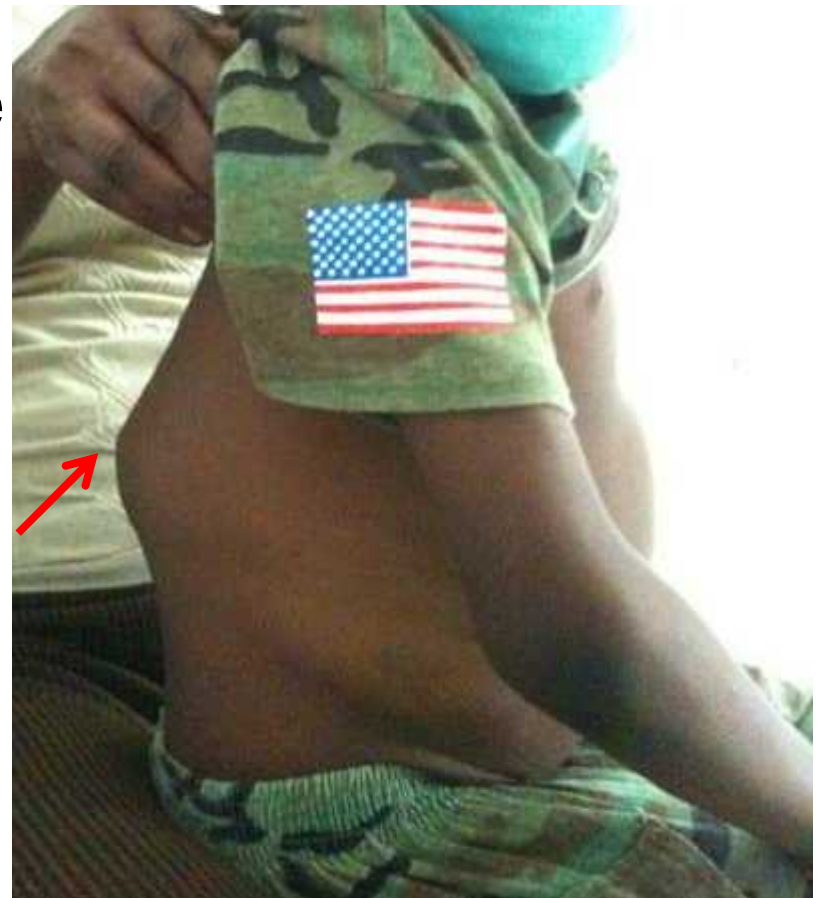- An ultrasonography usually shows matted loops of bowel with free fluid
- Peritoneal biopsy rarely done

CNS TB

- Most serious complication of TB in children
- TBM- metastatic caseous lesion in the cerebral cortex or meninges
- Brain stem commonest site-CN III, VI, VII
- Exudate obstructing CSF flow: hydrocephalus
- May progress rapidly over days (young infants)
- Or over weeks in 3 stages:
 - i) 1-2 wk: fever, headache, irritable, drowsy, malaise
 - ii) Lethargy, neck stiff, hypertonia, vomiting, CN palsies, disorientation
 - iii) Coma, hemi/paraplegia, hypertension, decortication, death

Skeletal Tuberculosis

- Pott's disease: Usually involves thoracolumbar spine
- Angulated kyphosis without scoliosis (Gibbus)
- Paraplegia
- Anterior erosion of vertebral bodies
- Large joint disease



Other Types of TB

Genitourinary TB: aseptic pyuria

Cutaneous TB:

- Different types, e.g. erythema nodosum, verrucous TB, chronic ulcers, scrofuloderma, tuberculoids, etc.
- Suspect cutaneous TB in chronic painless skin condition

Adrenal TB:

- Urinary frequency; Dysuria; Haematuria; Loin pain/swelling

Simplified Clinical TB Diagnosis

Presence of 2 or more of the following symptoms

Cough > 2weeks

Weight loss or poor weight gain

Persistent fever and/or night sweats > 2 weeks

Fatigue, reduced playfulness, less active

PLUS

Presence of 2 or more of the following:

Positive contact history

Respiratory signs

CXR suggestive of PTB (where available)

Positive Mantoux test (where available)

Then PTB is likely, and treatment is justified

**NO MORE
CRYING,
NO MORE
DYING.
TOWARDS
ZERO TB
DEATHS IN
CHILDREN.**



**Thank you for
your attention!**